

Surgical Management of Bilateral Congenital Cryptophthalmos in Dizygotic Twins of Lutino Cockatiel (*Nymphicus hollandicus*): A Case Report



Hemad Shafiei^{1*}, Hamzeh Soltaninejad¹, Mohammadreza Esmailinejad¹, Ali Keshavarzrad²

¹ Department of Clinical Sciences, Faculty of Veterinary Medicine, Shahid Bahonar University of Kerman, Kerman, Iran

² Faculty of Veterinary Medicine, Shahid Bahonar University of Kerman, Kerman, Iran

* Corresponding author email address: hemad.shafiei@uk.ac.ir

Article Info

Article type:

Case Report

How to cite this article:

Shafiei, H., Soltaninejad, H., Esmailinejad, M., & Keshavarzrad, A. (2025). Surgical Management of Bilateral Congenital Cryptophthalmos in Dizygotic Twins of Lutino Cockatiel (*Nymphicus hollandicus*): A Case Report. *Journal of Poultry Sciences and Avian Diseases*, 3(3), 70-74. <http://dx.doi.org/10.61838/kman.jpsad.3.3.9>



© 2025 the authors. Published by SANA Institute for Avian Health and Diseases Research, Tehran, Iran. This is an open access article under the terms of the Creative Commons Attribution 4.0 International (CC BY 4.0) License.

ABSTRACT

Cryptophthalmos is a rare congenital anomaly in birds that means "hidden eye" and generally manifests as fused eyelids that cover entirely the globe and eye socket. This report investigates a case of cryptophthalmos in two four-month-old same-hatch and gender-unknown Lutino Cockatiel (*Nymphicus hollandicus*). These two birds were referred to a specialized veterinary hospital for eye disorders. The diagnosis of bilateral congenital cryptophthalmos was confirmed after performing clinical examinations and ultrasound evaluation of the eye area. Following this diagnosis, corrective eyelid surgery was recommended to the bird's owner, successfully performed and accomplished. In addition, regular washing and topical treatment of the eyes in short intervals was recommended to prevent recurrence. Clinical follow-up within three weeks after surgery showed complete recovery and no recurrence of the complication. This report emphasizes the importance of surgical interventions and aftercare to improve this anomaly successfully.

Keywords: Bilateral Cryptophthalmos, Surgery, Lutino Cockatiel

1 Introduction

Cryptophthalmos is a congenital malformation in which the eyelids with a separate lid margin are not formed. This lesion can often be associated with the absence of eyelashes and eyebrows, as well as other developmental

abnormalities of the eye (1). On the other hand, ankyloblepharon is also considered a rare disorder in birds, which can be acquired due to the fusion of the eyelids or congenitally due to their failure to open (2). Cryptophthalmos can be confused with other eyelid abnormalities such as symblepharon, ankyloblepharon, and

Article history:

Received 13 March 2025

Revised 06 May 2025

Accepted 13 May 2025

Published online 01 July 2025

blepharophimosis due to clinical similarities (3, 4). This report provides effective diagnostic and treatment methods to improve this lesion.

2 Case Description

Two 4-month-old outbred Lutino Cockatiels (*Nymphicus hollandicus*) without eyelids with separate margins from birth in both eyes were referred to a specialized veterinary hospital (Figure 1). In the clinical examinations, the birds had a completely healthy clinical condition with weights of 77 and 74 grams and no other abnormalities. These two birds responded to light stimuli with different intensities, but with the change in the environment, they could not recognize the surrounding objects. According to these evaluations, complete and bilateral cryptophthalmos was diagnosed. The eyes of both birds were subjected to ultrasound evaluation to detect the full development of the eyeball. The ultrasonography technique was performed using the Mindray Z60 portable device and a microconvex multi-frequency probe with a small footprint and a frequency of 8.5 MHz adjusted for imaging. In the ultrasound, the eyeball structures of both birds could be adequately assessed. The anterior and posterior lens capsules appeared as hyperechoic lines. The anterior and vitreous chambers were observed as anechoic. (Figure 2 and Figure 3). Based on this, it was

decided to reconstruct the eyelids surgically using the gap technique.

Each bird was induced using a XXXS mask and an oxygen flow of 1.5 L/min and 2 MAC isoflurane. Then, they were intubated with an angicath as tracheal tube (Figure 4). Anesthesia was maintained with 1.5 MAC isoflurane using a T-Y Ayres closed breathing system. The oxygen flowmeter was set at approximately 1 L/min during this process. The eye surface was cleaned using betadine scrub 7.5%. An incision was made on both eyelids with the help of Metzenbaum scissors to prevent eye damage. After surgery, both birds were successfully recovered. Eye movement around, pupil response, and opening and closing of the third eyelid indicated healthy vision for both birds. To prevent eyelids from closing again, causing infection and dry eyes; artificial tear drops (Tearlose®, Sina Darou, Iran) every 30 minutes for 48 hours, ciprofloxacin eye drop 0.3% (Ciplex®, Sina Darou, Iran) one drop in each eye every 3 hours for up to 10 days, prednisolone acetate eye drops 1% (Precord®, Sina Darou, Iran) every 6 hours one drop in each eye for up to 4 days and vitamin A ointment (Xerovit®, Sina Darou, Iran) every 12 hours in each eye for up to 7 days was used. Clinical follow-ups within three weeks after the surgery, the edges of the eyelid were entirely repaired, and the complication did not recur (Figure 5).



Figure 1. Two four-month-old same-hatch and gender-unknown Lutino Cockatiel (*Nymphicus hollandicus*) with bilateral congenital cryptophthalmos.

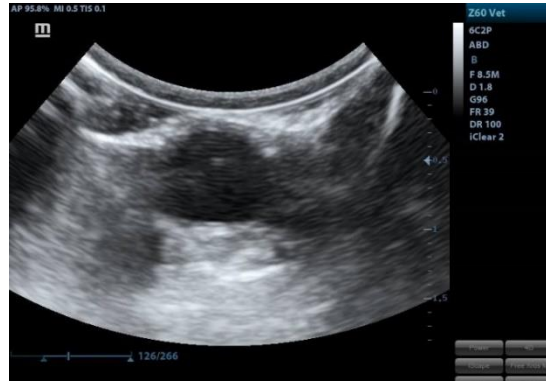


Figure 2. The retro-bulbar region and optic disk were also completely normal.

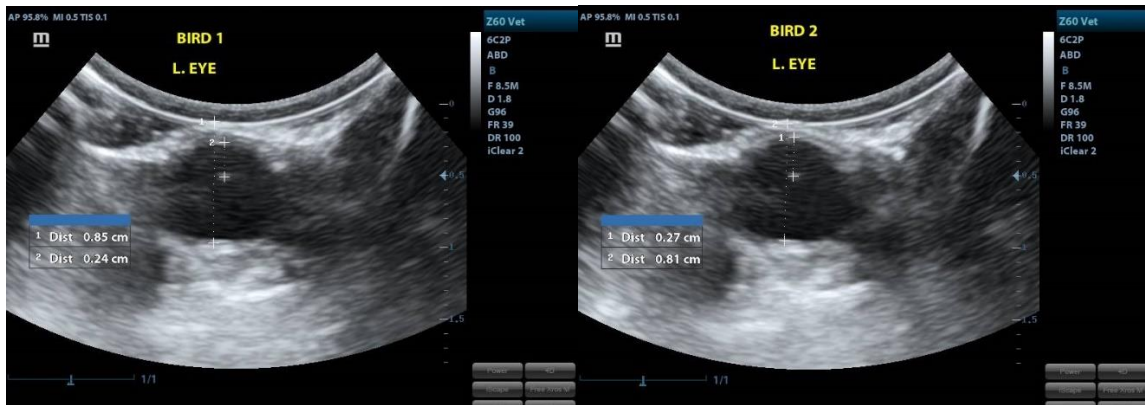


Figure 3. The anterior-posterior length of the lens and globe were measured in each eye and all four eyes were normal in size.

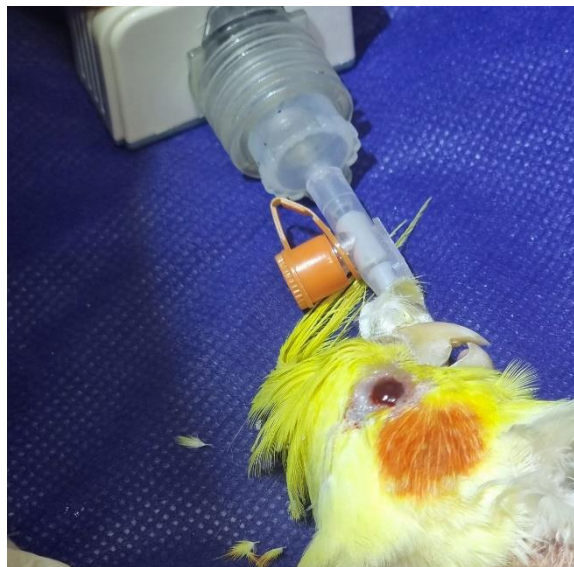

Figure 4. Both birds were intubated with an angicath as a tracheal tube



Figure 5. Appearance of the eyes in both birds 3 weeks after surgery. The edges of the eyelid were entirely repaired and the complication did not recur.

3 Discussion

Birds have a complex protective eye structure, including the upper and lower eyelids and the nictitans membrane. These anatomical components may be exposed to abnormalities affecting the bird's visual function and overall health (5). Eyelid abnormalities in birds can be congenital or acquired, unilateral or bilateral, or complete or incomplete. Among these abnormalities, we can mention cryptophthalmos, symblepharon, ankyloblepharon, and blepharophimosis (6).

Cryptophthalmos is a rare congenital malformation that appears with the extension of the eyelid on the eye, either completely or incompletely. In this abnormality, the eyeball structures are usually weakened, and vision is disturbed (7, 8). Cryptophthalmos is also known as eyelid atresia, which is mostly seen bilaterally; Its unilateral form is rare (1, 9). Ankyloblepharon is another eyelid abnormality that has many clinical similarities with cryptophthalmos. In addition to manifesting as a congenital form due to not opening the eyelids in time after birth, this abnormality can be acquired due to trauma in the eye area or infectious conflicts (1, 2). Symblepharon is also an abnormality that manifests as a result of partial or complete nictitan membrane adhesion to the eyeball's conjunctival part. Congenital symblepharon may be seen with cryptophthalmos (10, 11). Blepharophimosis syndrome also occurs due to genetic disorders. This syndrome is mainly characterized by features such as blepharophimosis (decrease in the width of the eyelid fissure), ptosis (drooping of the upper eyelid), epicanthus inversus (the presence of a skin fold in the lower

eyelid), and tele canthus (increasing the distance between the inner corners of the eyes) (12).

Among animals, only cases of cryptophthalmos have been reported in dogs and birds, which indicates the rare occurrence of this lesion in animals (6, 9, 13, 14). Cryptophthalmos in humans is known as Fraser syndrome, which is mainly seen with other abnormalities in the face and skull bones (1). In this report, cryptophthalmos was observed wholly and bilaterally, without any other abnormalities in both littermates. In some human studies, there have been reports about the genetic connection of this abnormality (15, 16).

4 Conclusion

Due to the authors' knowledge, this is the first report of congenital cryptophthalmos occurring in two Lutino Cockatiel (*Nymphicus hollandicus*) of the same age and resolved with successful surgical and post-surgical procedures. This report emphasizes the importance of surgical interventions in correcting congenital malformations and also the possibility of the occurrence of this malformation along with genetic disorders. Certainty, more extensive research is needed in this area.

Acknowledgements

The authors would like to express appreciation for the cooperation of Ashian Veterinary Hospital.

Conflict of Interest

The authors declare no competing interests.

Author Contributions

Hemad Shafiei: conceptualization, methodology, and writing- review and editing, Hamzeh Soltaninejad and Mohammadreza Esmaeilinejad: methodology; Ali Keshavarzrad: writing-original draft.

Data Availability Statement

The data used to support the findings of this study are available from the corresponding author upon request.

Ethical Considerations

In conducting this study, ethical principles have been fully observed.

Funding

This research did not receive any grant from funding agencies in the public (Universities, Veterinary Service Organizations), commercial, or non-profit sectors.

References

1. Jones KL, Jones MC, Del Campo M. Smith's recognizable patterns of human malformation: Elsevier Health Sciences; 2021.
2. Renée Schott, BS. Surgical Repair of Ankyloblepharon in Mallards (*Anas platyrhynchos*). Wildlife Rehabilitation Bulletin. 2008; 26 (2): 31-35.
3. Rival F. Congenital ankyloblepharon in a leopard gecko (*Eublepharis macularius*). Veterinary Ophthalmology. 2015;18:71-3. [PMID: 25053155] [DOI]
4. Ritchie BW, Harrison GJ, Harrison LR. Avian medicine: principles and application 1994.
5. del Rio AAB. THE EYE AND EYELIDS. Avian Medicine. 2015:64.
6. Demir A. Surgical Correction of Unilateral Congenital Cryptophthalmos in a Lutino Cockatiel (*Nymphicus hollandicus*). Turkish Veterinary Journal. 2019;1(2):106-9.
7. Salmon JF. Kanski's clinical ophthalmology e-book: a systematic approach: Elsevier Health Sciences; 2024.
8. Pourlis A. Developmental malformations in avian species. Manifestations of unknown or genetic etiology-a review. Asian Journal of Animal and Veterinary Advances. 2011;6(5):401-15. [DOI]
9. Buyukmihci NC, Murphy CJ, Paul-Murphy J, Hacker DV, Laratta LJ, Brooks DE. Eyelid malformation in four cockatiels. Journal of the American Veterinary Medical Association. 1990;196(9):1490-2. [PMID: 2341322] [DOI]
10. Şimşek CI, Ergin İ, Şenel OO. Surgical management of bilateral symblepharon accompanied by ankyloblepharon in a cat. Journal of Turkish Veterinary Medical Society. 96(1):62-7. [DOI]
11. Kern TJ, Paul-Murphy J, Murphy CJ, Buyukmihci NC, Burling K, Miller PE, et al. Disorders of the third eyelid in birds: 17 cases. Journal of Avian Medicine and Surgery. 1996:12-8.
12. Loffler KA, Zarkower D, Koopman P. Etiology of ovarian failure in blepharophimosis ptosis epicanthus inversus syndrome: FOXL2 is a conserved, early-acting gene in vertebrate ovarian development. Endocrinology. 2003;144(7):3237-43. [PMID: 12810580] [DOI]
13. Atabo S, Yuguda M, Ahmed S, Sanda M, Muazu T, Usman M. MANAGEMENT OF COMPLETE BILATERAL CRYPTOPHTHALMOS, CORNEAL DERMOID AND PERSISTENT IRIDOPUPILARY MEMBRANE IN TWIN UDA LAMBS IN KANO STATE, NIGERIA. Nigerian Journal of Animal Production. 2022:274-8.
14. Gelatt KN, Gelatt JP, Plummer C. Veterinary Ophthalmic Surgery-E-Book: Veterinary Ophthalmic Surgery-E-Book: Elsevier Health Sciences; 2021.
15. Chen H, Li S, Gao J, Cui G, Yang T, Zhao X. Genetic analysis of a fetus with cryptophthalmos due to variants of FREM2 gene. Zhonghua yi xue yi Chuan xue za zhi= Zhonghua Yixue Yichuanxue Zazhi= Chinese Journal of Medical Genetics. 2024;41(5):606-11.
16. Landau-Prat D, Kim DH, Bautista S, Strong A, Revere KE, Katowitz WR, et al. Cryptophthalmos: associated syndromes and genetic disorders. Ophthalmic Genetics. 2023;44(6):547-52. [PMID: 37493047] [DOI]