





Journal of Poultry Sciences and Avian Diseases

Journal homepage: www.jpsad.com



Case Report on Bacterial Infections, Newcastle Disease Seroconversion, and Aflatoxin Contamination in a Farm in Southwest Nigeria



Victor Agbajelola^{1,2*} , Precious Nwaoha¹ , Busola Oladeji³ 

¹ Department of Veterinary Pathobiology, University of Missouri, Columbia, 65211 MO, USA

² Department of Veterinary Medicine, University of Ibadan, 20005 Oyo State, Nigeria

³ College of Veterinary Medicine, Federal University of Agriculture, Abeokuta, 11011 Ogun State, Nigeria

* Corresponding author email address: vianh2@missouri.edu

Article Info

Article type:

Case Report

How to cite this article:

Agbajelola, V., Nwaoha, P., & Oladeji, B. (2025). Case Report on Bacterial Infections, Newcastle Disease Seroconversion, and Aflatoxin Contamination in a Farm in Southwest Nigeria. *Journal of Poultry Sciences and Avian Diseases*, 3(2), 62-65. <http://dx.doi.org/10.61838/kman.jpsad.3.2.8>



© 2025 the authors. Published by SANA Institute for Avian Health and Diseases Research, Tehran, Iran. This is an open access article under the terms of the Creative Commons Attribution 4.0 International (CC BY 4.0) License.

ABSTRACT

This case report details a multifactorial health challenge affecting a 28-week-old flock of 4,524 Arbor Acre broiler breeders on a commercial poultry farm in Southwest Nigeria. The flock presented with respiratory distress, neck twisting, and increased mortality. Postmortem findings included mucoid tracheitis, fibrinous pericarditis, friable livers, and bleached intestines. Diagnostic investigations identified systemic bacterial infection, adequate Newcastle disease vaccine seroconversion (titers $\geq 1:16$), and severe feed contamination with aflatoxin (315 ppb), far exceeding the permissible limit of 20 ppb for poultry feed. Heavy growth of lactose-fermenting bacteria was isolated from tissue samples, prompting antibiotic sensitivity testing, which identified enrofloxacin and ceftriaxone as effective treatments. The elevated aflatoxin levels likely contributed to immunosuppression and impaired flock productivity. Interventions included administering toxin binders, liver tonics, and iodine solutions and replacing contaminated feed. This case underscores the critical importance of integrated diagnostic approaches, targeted antimicrobial therapy, and stringent feed quality control in managing complex poultry health challenges.

Keywords: Breeder broilers, Aflatoxin, Newcastle disease, seroconversion, poultry farm

Article history:

Received 06 December 2024

Revised 23 January 2025

Accepted 01 February 2025

Published online 01 April 2025

1 Introduction

Poultry farming is a cornerstone of agricultural systems in Nigeria, particularly in the southwestern region, where it plays a critical role in food security and economic development (1). Broiler breeders, such as the Arbor Acre strain, are indispensable in poultry production systems, serving as the primary source of commercial day-old chicks (2). Maintaining the health and productivity of these breeder flocks is essential for sustaining poultry supply chains and meeting the growing demand for poultry products. However, broiler breeders are uniquely susceptible to various health challenges, including bacterial infections, viral diseases, and feed-related toxicities (3). These health issues can adversely impact reproductive performance, chick viability, and farm profitability (1, 4). Addressing these challenges requires integrated diagnostic and management strategies to safeguard flock health and optimize productivity.

This report describes a health crisis in a flock of 28-week-old Arbor Acre broiler breeders on a commercial farm in Akure, Southwest Nigeria. The flock presented with respiratory and neurological signs, alongside mortality patterns, raising suspicion of bacterial infections, suboptimal Newcastle disease seroconversion, and aflatoxin-induced

mycotoxicosis. This case illustrates the value of integrated diagnostic approaches, combining bacterial culture, serological assays, and feed analysis to identify and address multifactorial health challenges in broiler breeder production systems.

2 Case Description

A flock of 4,524 28-week-old Arbor Acre broiler breeders exhibited respiratory and neurological signs such as sneezing, ocular discharge, and neck twisting referred to our clinic. These clinical signs emerged approximately four weeks after administering a Mycoplasma vaccine. The flock was managed to produce commercial day-old chicks and was maintained on commercial feed and water sourced from a local borehole. Concerns about significant economic losses arose due to increased mortality rates.

Postmortem examination revealed notable lesions, including mucoid tracheitis, fibrinous pericarditis, perihepatitis, and peritonitis, which are indicative of systemic bacterial infection. Additional findings included friable, discolored livers and pale intestines, suggesting potential feed-related mycotoxicosis, likely due to aflatoxin contamination (Figure 1).

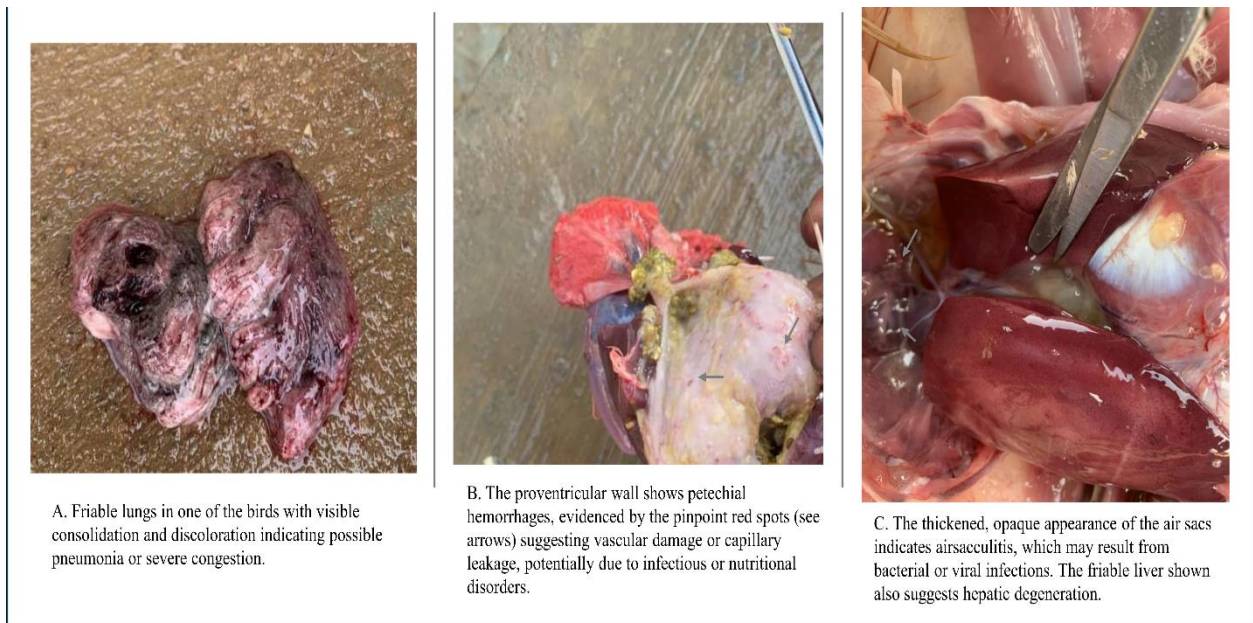


Figure 1. Representative postmortem lesions were observed in affected birds.

Based on these findings, systemic bacterial infections were suspected. Tissue samples from the heart, lungs, liver, and spleen were submitted for laboratory testing to assess

antibiotic susceptibility, as the flock had been treated with antibiotics without clinical improvement.

Serum samples were analyzed using hemagglutination inhibition assays to determine post-vaccination antibody

titers against Newcastle Disease Virus (NDV). Geometric mean titers (GMT) were calculated to evaluate seroconversion rates.

Following reports of water accumulation in the animal pens resulting from significant rainfall, there were concerns that these conditions could promote fungal contamination of the feed. This raised concerns about aflatoxicosis as a contributing factor. Consequently, feed samples were analyzed for aflatoxin contamination. Optical density at 450 nm was measured, and results were expressed in parts per billion (ppb) for comparison with permissible limits for poultry feed (5).

3 Results and Discussion

Bacterial culture from tissue samples revealed a heavy growth of lactose-fermenting bacteria isolated from the heart, lung, liver, spleen, and fibrinous exudates. Although the specific bacterial species were not identified, the primary aim was to determine the reasons for the flock's lack of response to prior antibiotic treatments. Antibiotic sensitivity testing demonstrated high efficacy of enrofloxacin and ceftriaxone, whereas resistance was observed against colistin, erythromycin, and streptomycin. These findings confirmed the presence of systemic bacterial infections and underscored the necessity for targeted antimicrobial therapy to improve treatment outcomes. However, comparing mortality rates and productivity metrics before and after intervention was impossible due to incomplete farm records.

Serological analysis indicated protective NDV antibody titers in all sampled birds, with titers $\geq 1:16$, demonstrating immunity against field strains of the virus. Geometric mean titers (GMT) ranged from 10.9 (1:1024) to 11.8 (1:2048), with a modal titer of 1:4096 across samples. Seroconversion was observed in 70–100% of birds, consistent with expected responses to NDV oil/inactivated vaccines. These results confirm that NDV vaccination provided protective immunity, reducing the risk of Newcastle disease outbreaks.

Feed analysis revealed an alarming aflatoxin concentration of 315 ppb, significantly exceeding the permissible limit of 20 ppb for poultry feed (5). The elevated aflatoxin levels likely contributed to the systemic health issues observed in the flock, including immunosuppression, poor vaccine seroconversion, and delayed reproductive performance (6). Aflatoxicosis is well-documented for its adverse effects in poultry, including immunosuppression, reduced growth, skeletal deformities, and decreased productivity (6, 7).

This case underscores the multifactorial nature of health challenges in broiler breeders, particularly the interplay between bacterial infections and feed-related toxicity. The antibiotic sensitivity profile highlighted enrofloxacin as an effective therapeutic option. Nevertheless, the indiscriminate use of antibiotics in poultry management poses significant risks, including the development of antimicrobial resistance (AMR), which diminishes treatment efficacy and limits future options for disease control. These findings emphasize the importance of judicious antibiotic use, guided by diagnostic testing, and the integration of alternative control measures such as enhanced biosecurity, vaccination programs, and probiotics.

Additionally, the results highlight the critical role of integrated diagnostic approaches in poultry health management. Although NDV vaccination achieved protective antibody titers, the excessive aflatoxin burden likely undermined the flock's overall health and productivity. Addressing feed quality through stringent monitoring and implementing robust biosecurity measures are essential for mitigating similar health challenges and optimizing breeder flock performance. This report provides actionable insights into managing complex health issues in commercial poultry production systems.

4 Conclusion

This case report provides valuable insights into the complex interplay of bacterial infections, aflatoxin contamination, and vaccine efficacy in broiler breeder health. Its emphasis on integrated diagnostics and actionable interventions makes it a valuable resource for poultry health management. However, limitations in bacterial identification, exploration of aflatoxin sources, and statistical analysis constrain the broader applicability of its findings. Future studies should address these gaps to enhance the understanding and management of multifactorial health challenges in poultry farming.

Acknowledgements

The authors thank Mr. Segun Raheem for providing the data used in this study. Special thanks also go to Dr. Yemi Bolatito of the Animal Care Technical Services Division, Nigeria, for their invaluable assistance with laboratory diagnostics.

Conflict of Interest

The authors declared no conflicts of interest.

Author Contributions

Victor Agbajelola: Conceptualization, methodology, writing, and review and editing of the manuscript. Precious Nwaoha and Busola Oladeji: Methodology and proofreading of the manuscript.

Data Availability Statement

Data are available from the first author upon reasonable request.

Ethical Considerations

This case report adhered to all relevant ethical principles.

Funding

None.

References

1. Adene DF, Oguntade AE. The structure and importance of the commercial and village-based poultry industry in Nigeria: ECTAD/AGAP; 2006. p102.
2. Vijayalingam TA, Rajesh NV, Ilavarasan S. A case report of aflatoxicosis in a country chicken unit with retarded egg production. *International Journal of Current Microbiology and Applied Sciences*. 2017; 6(12). [DOI]
3. Aly SA, Anwer W. Effect of naturally contaminated feed with aflatoxins on performance of laying hens and the carryover of aflatoxin B residues in table eggs. *Pakistan Journal of Nutrition*. 2009;8:181-6. [DOI]
4. Alexander DJ. Newcastle disease and other avian Paramyxoviridae infections. 2003. p 63-87.
5. National Agency for Food, Drug Agency, Control. Animal Feed Premix Registration Regulations 2023.
6. Abedi A, Talebi E. Effect of aflatoxins on poultry production and control methods of destructive influence. *ARNP Journal of Agricultural and Biological Science*. 2015:441-6.
7. Kovacs MC. Nutritional health aspects of mycotoxins. *Orv Hetil*. 2004;22:1739-46.